

SCANDINAVIAN JOURNAL  
OF  
Plastic and  
Reconstructive  
Surgery

Chief Editor: BENGT JOHANSON, Göteborg  
Co-Editor: ODDVAR EIKEN, Malmö  
Assistant Editor: JAN LILJA, Göteborg

Editorial Board:

P. FOGH-ANDERSEN Copenhagen	LARS HAKELIUS Uppsala
HALFDAN SCHJELDERUP Bergen	AARNE RINTALA Helsinki

Vol. 20 1986

## INDEX

### No. 1

- Bengt Nylén, M.D. In Memoriam 1
- P. Tessier and D. Hemmy (Suresnes, France and Milwaukee, USA): Three dimensional imaging in medicine. A critique by surgeons 3
- D. B. Apfelberg (Palo Alto, USA): Summary of argon laser usage in plastic surgery 13
- D. B. Apfelberg (Palo Alto, USA): Summary of carbon dioxide laser usage in plastic surgery 19
- W. T. Theuvsen, G. F. Koeyers and M. H. M. Borgehouts (Nijmegen, The Netherlands): Thermographic assessment of perforating arteries. A preoperative screening method for fasciocutaneous and musculocutaneous flaps 25
- K. Inoue and K. Matsumoto (Hamamatsu, Japan): Quantification of texture match of the skin graft: Function and morphology of the stratum corneum 31
- J.-P. A. Nicolai, M. Y. Bos and B. G. A. ter Haar (Arnhem and Nijmegen, The Netherlands): Hereditary congenital facial paralysis 37
- A. Massei (Pisa, Italy): Reconstruction of cleft maxilla with periosteoplasty 41
- A. Rintala, E. Martinen, S.-L. Rantala and I. Kaitila (Helsinki, Finland): Cleft palate in diastrophic dysplasia. Morphology, results of treatment and complications 45
- H. Holmström (Göteborg, Sweden): The Abbe flap converted to an island flap 51
- M. Lejour, J. Duchateau and A. Potaznik (Brussels, Belgium): Routine reinsertion of the hump in rhinoplasty 55
- R. Gumener, D. Montandon, F. Marty and A. Zbrodowski (Geneva, Switzerland): The subcutaneous tissue flap and the misconception on fasciocutaneous flaps 61
- F. V. Nicolle (London, United Kingdom): Secondary rhinoplasty of the nasal tip and columella. The choice of cartilage grafts 67
- D. E. Tolhurst (Rotterdam, The Netherlands): Clinical experience and complications with fasciocutaneous flaps 75
- Y. Maruyama, K. Onishi and Y. Iwahira (Tokyo, Japan): Reconstructing chest walls with vertical abdominal fasciocutaneous flaps 79
- S. Teich-Alasia, G. Ambroggio, E. Oberto, V. Cerutti and A. Perla (Torino, Italy): A subscapular-pubic fasciocutaneous flap for reconstruction of the chest wall following excision to the extent of near inoperability 85
- P. Santi, P. Berrino, A. Galli, C. Quondamcarlo and M. L. Rainero (Genova, Italy): Anterior transposition of the latissimus dorsi muscle through minimal incisions 89
- N. Bricout and P. Banzet (Paris, France): Rectus abdominis myocutaneous flap of the lower type in breast reconstruction 93
- A. Scrocca and G. Petrella (Napoli, Italy): Breast reconstruction according to pTNM: Our experience 97
- L. Meyer and A. Ringberg (Lund and Malmö, Sweden): A prospective study of psychiatric and psychosocial sequelae of bilateral subcutaneous mastectomy 101

- L. P. Weinstein, D. Kovachev and T. Chaglassian (New York, USA): Abdominal wall reconstruction 109
- D. Dioguardi and M. Pascone (Bari, Italy): Dermal-fat flaps in the treatment of large post-incisional hernias ("Cross-over flap" technique) 115
- H. Kjeldsen and B. N. Gregersen (Århus, Denmark): Giant incisional hernias closed with polypropylene mesh 119
- M. Pers, K. Snorrason and I. M. Nielsen (Copenhagen, Denmark): Primary results following surgical treatment of pressure sores 123
- H. Reichert (Stuttgart, West Germany): Surgical treatment of pressure sores in paraplegics and possible prevention of their recurrence 125
- C. Kauer and G. Sonsino (Berck, France): The need for skin and muscle saving techniques in the repair of decubitus ulcers. A case report 129
- M. C. Ferreira, G. Gabbianelli, N. Alonso and C. Fontana (Sao Paulo, Brasil): The distal pedicle fascia flap of the leg 133
- H. Hammer, I. Bugyi and P. R. Zellner (Ludwigshafen-Oggersheim, West Germany): Soft tissue reconstruction of the anterior surface of the lower leg in burn patients using a free latissimus dorsi muscle flap 137
- R. G. Baumeister, S. Siuda, H. Bohmert and E. Moser (München, West Germany): A microsurgical method for reconstruction of interrupted lymphatic pathways: Autologous lymph-vessel transplantation for treatment of lymphedemas 141
- F. Mussinelli, A. Carù and T. L. Cipollini (Milano, Italy): Trends in conservative clitoroplasty 147
- A. Berger (Hannover, West Germany): Reconstruction of the thenar muscles by microsurgery 153

### Announcements 157

### No. 2

- L. F. Solheim, H. Rønningen, E. Barth and N. Langeland (Oslo, Norway): Effects of acetylsalicylic acid and naproxen on the mechanical and biochemical properties of intact skin in rats 161
- L. Wetter, M. S. Ågren, G. Hallmans, I. Tengrup and F. Rank (Umeå, Lund and Malmö, Sweden): Effects of zinc oxide in an occlusive, adhesive dressing on granulation tissue formation 165
- P. Thomsen, L. M. Bjursten and L. E. Ericson (Göteborg, Sweden): Implants in the abdominal wall of the rat 173
- T. Lähteenmäki (Helsinki, Finland): The regeneration of adrenergic nerves in a free microvascular groin flap in the rat 183
- I. Blomgren and H. Holmström (Göteborg, Sweden): Anterior levator resection in congenital genuine blepharoptosis 189
- H. Holmström and I. Blomgren (Göteborg, Sweden): Simple adaptation of Müller's muscle to the tarsal plate in congenital blepharoptosis. A preliminary report 197
- C. Lauritzen, B. Vällfors and J. Lilja (Göteborg, Sweden): Facial disassembly for tumor resection 201

C. G. Hagert, P. I. Brånemark, T. Albrektsson, K. G. Strid and L. Irstam (Göteborg, Sweden): Metacarpophalangeal joint replacement with osseointegrated endoprostheses 207

J. Holmberg and L. Ekerot (Malmö, Sweden): The free scapular flap. An alternative to conventional flaps on the upper extremity 219

L. Ekerot, K. Jonsson and L. E. Necking (Malmö, Sweden): Wrist denervation and compression of the lunate in Kienböck's disease 225

L. E. Necking and O. Eiken (Malmö, Sweden): ECRL-strip plasty for metacarpal base fixation after excision of the trapezium 229

#### Case Reports

C. J. Edeling, K. Snorrason and S. Medgyesi (Copenhagen, Denmark): An atypical case of lupus miliaris faciei simulating dermoid cyst: diagnostic and therapeutic difficulties. Case report 235

O. Engkvist and F. af Ekenstam (Uppsala, Sweden): Closed dislocation of the scaphoid. A case report and review of the literature 239

O. Engkvist (Uppsala, Sweden): The effect of regional intravenous guanethidine block in acute frostbite. Case report 243

#### Announcements 247

##### No. 3

Atso Soivio. In memoriam 249

B. Widenfalk, O. Engkvist, L. Ohlsén and K. Segerström (Uppsala, Sweden): Perichondrial arthroplasty using fibrin glue and early mobilization. An experimental study 251

L. Ohlsén and U. Nordin (Uppsala and Stockholm, Sweden): Experimental laryngeal reconstruction with preformed composite graft 259

A. J. Radek (Łódź, Poland): Blood supply of transected

rabbit peripheral nerve after end-to-end suture or autogenous grafting. A microangiographic study 273

G. Lundborg, L. B. Dahlin, N. Danielsen and A. K. Nachemson (Lund and Göteborg, Sweden): Tissue specificity in nerve regeneration 279

J. Holmberg, L. Ekerot and S. Sälgeback (Malmö, Sweden): Flap coverage for post-traumatic nerve pain in the arm 285

L.-Å. Broström, A. Stark and G. Svartengren (Stockholm, Sweden): Non-union of the scaphoid treated with styloidectomy and compression screw fixation 289

L. Ekerot, J. Holmberg and I. Niechajew (Malmö, Sweden): Thumb replantation or not? 293

H. Jousimies-Somer, R. Grénman and A. Rintala (Helsinki, Finland): Bacteriological investigation of secretory otitis media in children with cleft palate 297

R. Källén, A. Broomé, A. Mühlow and N. Forsby (Helsingborg, Sweden): Reduction mammoplasty: Results of preoperative mammography and patient inquiry 303

#### Case Reports

F. N. Abu Jamra, M. Massad and R. C. Musharrafieh (Beirut, Lebanon): Reconstruction of shoulder and arm defects using the latissimus dorsi myocutaneous flap. A report of five cases 307

H. Holmström, M. Suurkula and C. Lossing (Göteborg, Sweden): Absent latissimus dorsi muscle and anhidrotic axilla in Poland's syndrome. Case report 313

I. Fögdestam and J. Lilja (Göteborg, Sweden): Microsurgical replantation of a total scalp avulsion. Case report 319

O. P. Jakobsson and J. Bergh (Uppsala, Sweden): Acral lentiginous malignant melanoma. Case Report 328

I. Blomgren, J. Lilja, C. Lauritzen and B. Magnusson (Göteborg, Sweden): Multiple craniofacial surgical interventions during 25 years of follow-up in a case of giant fibrous dysplasia. Case report 327

O. J. Einarsson and M. Pers (Copenhagen, Denmark): Streptococcal gangrene of the eyelids. Case reports 331

#### Announcements 337

ISSN 0036

# Scandinavian Journal of **Plastic and Reconstructive Surgery**

Vol. 20. 1986. No.



*Chief Editor:*  
*Bengt Johanson, Göteborg*  
*Co-Editor:*  
*Oddvar Eiken, Malmö*  
*Assistant Editor:*  
*Jan Lilja, Göteborg*

*Distributed by The Almqvist & Wiksell Periodical Company, Stockholm, Sweden*

## RECONSTRUCTION OF CLEFT MAXILLA WITH PERIOSTEOPLASTY

Alessandro Massei

*From the Department of Plastic Surgery, S. Chiara Hospital, Pisa, Italy*

**Abstract.** The principle of gnatoplasty using local periosteal flaps according to Skoog is employed, but an essential modification in reconstructing the cleft maxilla is suggested. The periosteum of the anterior aspect of the maxilla is transferred as an island flap instead of using it as a precarious pedicle flap. The island flap is based on the cheek tissues lying over the periosteum, thereby including the insertions of the mimic muscles. The vascular supply and the osteogenic activity of the periosteum is preserved, and satisfactory new bone production is obtained.

**Key words:** cleft maxilla, periosteoplasty, gnatoplasty.

Over the last eight years, we have, in our department, performed surgery on about two hundred clefts of the maxilla according to an original method already described in previous papers (1, 2, 3).

Since 1966 we have been following Skoog's principles, according to which the repair of the cleft lip is incomplete without the simultaneous reconstruction of the bone defect in the maxilla by periosteoplasty. If the repair of the cleft maxilla in reconstructing the lip is neglected, there is a risk of collapse of the lateral segment of the maxilla, due to the pressure exerted by the repaired lip on the unjoined lateral segment of the maxilla. Furthermore, the forward growth of the growth centres of the middle third of the face being separated by the cleft is not coordinated. According to Skoog, coordination of these forces can be obtained by reconstructing the maxillary continuity by periosteal flaps at the same time as the cleft lip is repaired (5, 6, 7, 8, 9, 10). However, in a number of cases we found that periosteal flaps transposed according to the Skoog method resulted in inadequate or altogether lacking bone production (3, 11). We realized that the method using the pedicle flap from the anterior aspect of the maxilla presents technical difficulties which are sometimes so hard to overcome that the flap had to be used as a free graft.

The vascular supply and the osteogenic activity of that flap is often damaged, it being very thin and disconnected both from the maxilla and from the overlying soft tissues, stretched like a bridge over the cleft, and sometimes twisted on the pedicle. This flap is the Achilles' heel of Skoog's periosteoplasty. However, the remaining part of the periosteal lining appears to be vital enough. This experience demonstrates that satisfactory bone production can only be achieved if the flaps forming the periosteal closed pocket have full vitality. On the basis of my experience of Skoog's "Repeated Periosteoplasty" (10) the idea of a new form of primary periosteoplasty was born. My plan was to set a different flap build the anterior surface of the periosteal pocket. A flap that is not obtained by transposition of a simple periosteal flap, but by the forward and medial sliding of most of the periosteum of the maxillary anterior aspect together with the whole soft tissue complex overlying it, and not disconnected from the periosteum itself. The periosteum of the anterior face of the maxilla raised from it and incised all around is dissected off like an island flap based on the overlying soft tissues. The vitality and the osteogenic activity of the periosteum is preserved, thanks to the untouched vascular supply and the functional pouches of the muscular insertions: m. caninus, m. incisivus labii superioris, m. depressor alae nasi. The necessity of maintaining the connection between the periosteum and the overlying soft tissues, with the muscles inserted in it, has been emphasized by various authors since the eighteenth century (4, 12).

### MATERIAL AND METHOD

During the last eight years 204 maxillary clefts have been repaired according to this technique: 107 complete unilateral clefts, 13 unilateral incomplete clefts, 76 bilateral



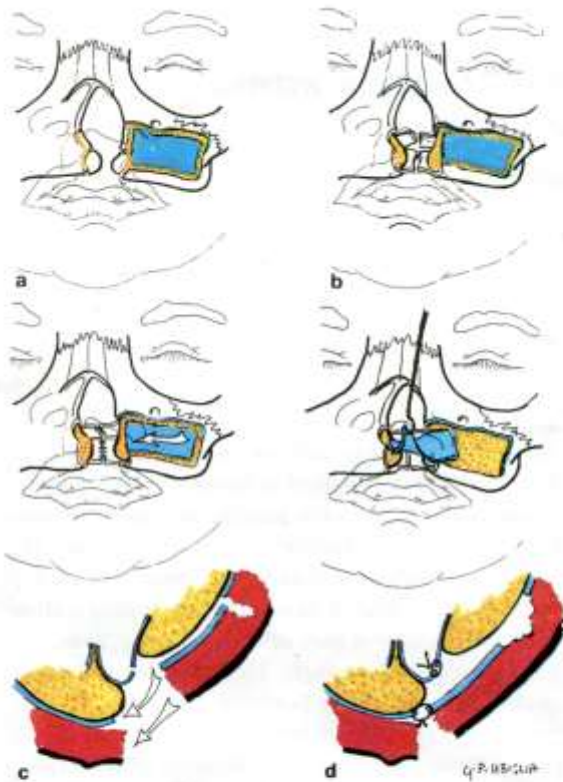


Fig. 1. (a, b) The bottom of the periosteum-lined pocket is made; the periosteum of the anterior aspect of the maxilla is detached from the bone, incised all around. (c) Blunt dissection along the incision mobilizes the periosteal island flap. (d) The island flap of the periosteum is sutured to the premaxilla like a curtain over the cleft.

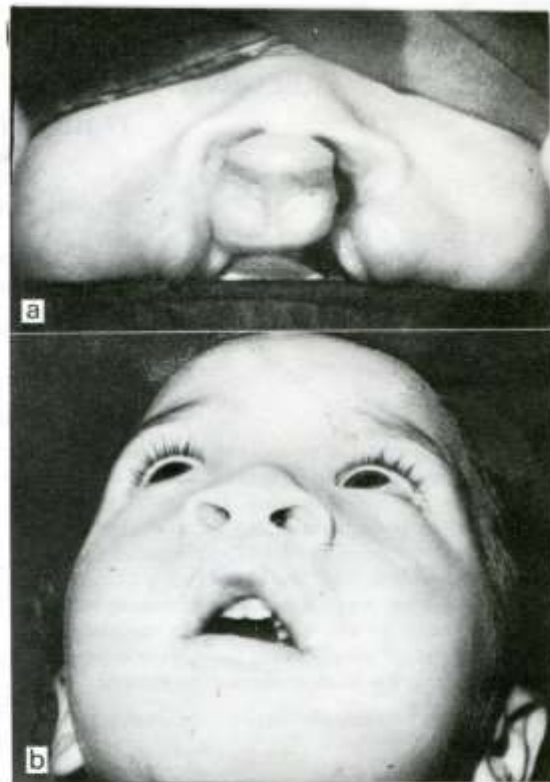


Fig. 2. P. Matteo, (a) a three-month-old child with bilateral cleft lip and protrusion of the premaxillary segment. (b) Characteristic residual defect at four years of age. The lip was repaired in two stages according to Skoog; periosteoplasty was performed as described in the text.

complete clefts, and 8 bilateral incomplete clefts. Thirty-four patients had already undergone primary cheilognathoplasty according to Skoog which had not been followed by bone production.

Incisions are made through the skin, muscles and mucosa of the lip according to Skoog. To perform gnatoplasty we create a periosteal three-faced pocket between the bony surface of the cleft. The inner periosteal lining consists of two of these faces. They are formed by flaps of mucoperiosteum dissected from the bony surfaces facing the cleft (Fig. 1). These flaps are not obtained according to a rigid pattern, but their planning can easily be adapted to the individual situation. Keen examination will allow recognition of the border on the mucosa facing the cleft between the oral and nasal mucosa. It is advisable to make the incisions along these border lines so that, at the end of reconstruction, the nasal floor will be formed by mucoperiosteum of the nose, and the oral side will be reconstructed by mucoperiosteum of the mouth. The flaps forming the oral face of the primary palate, in particular, are made and positioned with their mucous side toward the tongue. To build the flaps forming the nasal side of the primary palate,

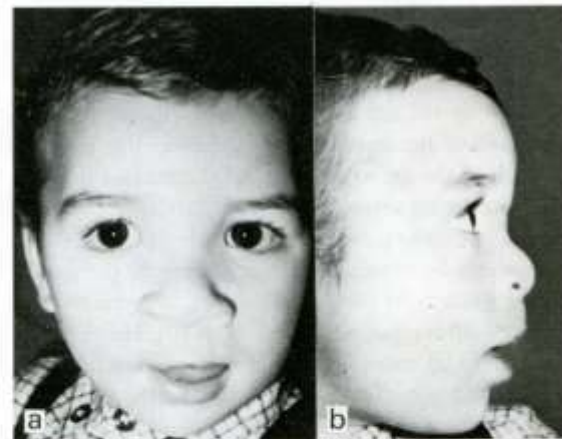


Fig. 3. The same patient as in Fig. 2. Short columella, no surgery has been performed on the nose until now. The good position of the alar base is obtained only by the periosteoplasty.

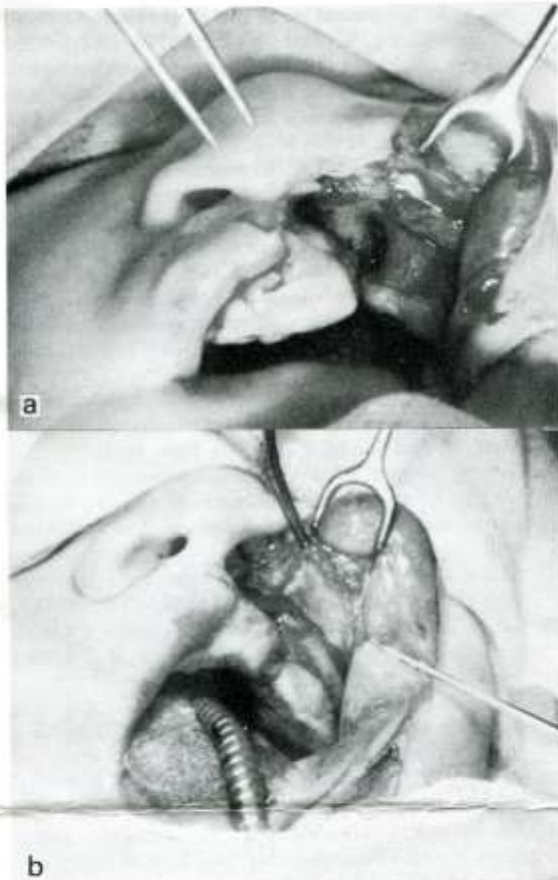


Fig. 4. The same patient, seven months old, at the second side repair. (a) The original bone defect is easily seen; the maxilla is stripped and the nasal floor is made with mucoperiosteum from the medial aspect of the maxilla. (b) The periosteum of the anterior aspect of the maxilla, detached from the bone and incised all around as an island flap is ready to migrate medially.

the anterior part of the medial aspect of the maxilla is stripped, the mucoperiosteum is brought medially and sutured to a mucopericondrial flap from the septum. The oral and the nasal sides of the primary palate thus reconstructed form a dihedral angle with its opening towards the surgeon. It represents the bottom of the periosteum-lined pocket (Fig. 1). Any tension on the sutures of the flaps must be avoided. In order to do this, raw areas may result. It is advisable to repair these with free skin or mucosal grafts to await scarring (11). The incision is now extended laterally along the buccal sulcus. This incision is made in the transitional area between the adherent and mobile gum, through mucosa and periosteum down to the bone. The periosteum of the anterior aspect of the maxilla is detached from the bone, reaching the piriform opening medially, the infra-orbital foramen upwards, and the origin of the zygomatic process laterally. The periosteum is incised all around these

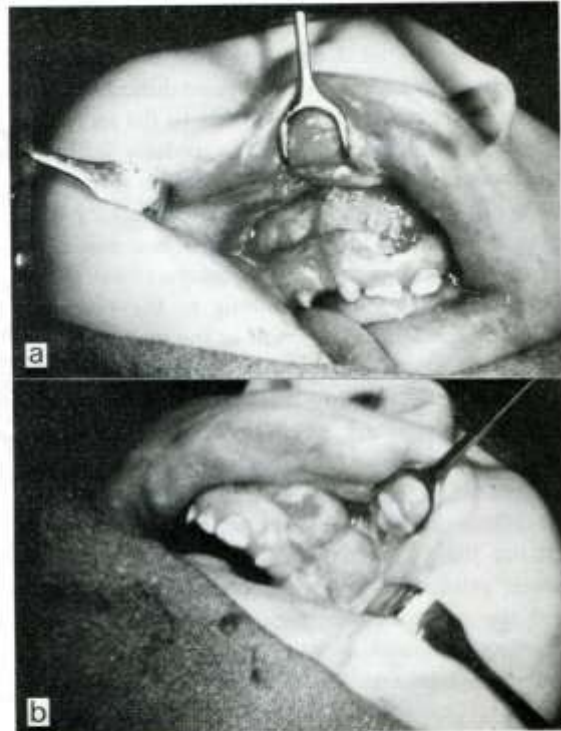


Fig. 5. In conjunction with the palatoplasty, at two years of age, both maxillary clefts are reexposed. Good bone continuity can be observed bilaterally as a result of the periosteoplasty.

borders (Fig. 1). Blunt dissection along the incision mobilizes the flap enough to allow it to be sutured to the premaxilla without tension (Fig. 1, Fig. 4). The periosteum of the anterior aspect of the maxilla in block with all the overlying tissues is drawn up like a curtain over the cleft (Fig. 1) which is kept under tension by the preserved muscle insertions. The maxillary periosteum, the muscles inserted in it, the overlying skin, and the alar base can thus migrate to their correct anatomical positions and bone production is then a compulsory consequence (Fig. 5).

## RESULTS

The new bone production was satisfactory in most cases (Fig. 5), as was confirmed both by clinical and radiological investigation. We tested surgically 116 clefts out of 204. Among these, 101 cases presented satisfactory definite bone production, 7 cases showed inadequate bone production, in 5 unilateral cases there was no bone production at all, and in 3 bilateral cases there was no bone production on one side and definite bone production on the other one.

## DISCUSSION

Despite the detailed description of the technique given here, its execution involves no difficulties. The pattern is not rigid, but adaptable to the individual situation. Moreover, the periosteoplasty facilitates the cheiloplasty by removing any tension at the stage of the lip repair (Figs. 2, 3). The satisfactory bone production found in the majority of our cases confirms the existence of osteogenic activity in the periosteal flaps made according to the described method. As far as the growth of the maxilla is concerned, Skoog proved that it was not harmed by the periosteoplasty; shortly after the withdrawal the maxilla is completely covered with periosteum again (4, 10). In any case, the periosteoplasty I propose utilizes the same area as Skoog's periosteoplasty, and no different or more serious damage can be inflicted on the juvenile maxilla. With this technique the Skoog principles for periosteoplasty are still valid and the periosteum of the anterior aspect of the maxilla medialized with the overlying cheek tissues will surely reproduce a new maxilla in a more correct position. Consequently the mimic muscles, the lip, and the alar base of the nose are easily repositioned.

## REFERENCES

1. Massei A, Ubiglia GP. Comunicazione preliminare sull'uso di un lembo periosteale modificato per la ricostruzione del mascellare in casi di gnatoschisi operati secondo Skoog. *Riv Ital Chir Plast* 1979; 11: 219-226.
2. Massei A, Ubiglia GP. Evoluzione nella ricostruzione della schisi mascellare mediante lembi periosteali. *Atti 28° Congresso nazionale della Società Italiana di Chirurgia Plastica*, Sevilla 1979, 189-190.
3. Massei A, Ubiglia GP. Ricostruzione alveolare con lembo di periostio mascellare, combinato a lembi periosteali locali. *Atti del 29° Congresso nazionale della Società Italiana di Chirurgia Plastica*, Taormina, 1980, 41-44.
4. Ollier L. *Traité expérimental et clinique de la régénération des os et de la production artificielle du tissu osseux*. V. Masson et Fils, Paris, 1867, Tome II: 449-459.
5. Santoni Rugiu P. La ricostruzione dell'arcata alveolare con lembi periosteali nella labiognatopalatoschisi completa. *Bollett Soc Med Chir Pisa* 1966; 34: 1.
6. Santoni Rugiu P, Massei A. La reconstruction de la fissure maxillaire avec des lambeaux de périoste dans le cas de fente labio-palatine complète. *Ann Chir Plast* 1971; 16: 326-333.
7. Skoog T. The use of periosteal flaps in the repair of cleft of the primary palate. *Cleft Palate J* 1965; 2: 332.
8. Skoog T. The use of periosteum and Surgicel® for bone restoration in congenital clefts of the maxilla. *Scand J Plast Reconstr Surg* 1967; 1: 113.
9. Skoog T. Repair of unilateral cleft lip deformity: maxilla, nose and lip. *Scand J Plast Reconstr Surg* 1969; 3: 109.
10. Skoog T. *Plastic surgery*. Stockholm: Almqvist & Wiksell International, 1974, 35-142.
11. Stenström S, Thilander B. Management of cleft palate cases. *Scand J Plast Reconstr Surg* 1974; 8: 6-72.
12. Troja M. *Esperienze intorno alla rigenerazione dell'ossa*. Napoli: Stamperia Simoniana, 1779.